

B10.4

Evaluation of the main spatial angles in adolescent idiopathic scoliosis optically diagnosed

Sasa Cukovic¹, William R. Taylor¹, Vanja Luković², Christoph Heidt³, Radu Petrus⁴, Subburaj Karupppasamy⁵¹ Institute for Biomechanics, ETH Zürich, Laboratory for Movement Biomechanics, Zürich, Switzerland² University of Kragujevac, Faculty of Technical Sciences Čačak, Čačak, Serbia³ University Children Hospital - UKBB Basel, Basel,⁴ "Lucian Blaga" University of Sibiu, Sibiu, Romania⁵ Singapore University of Technology and Design, Singapore, Singapore

Clinical evaluation of Adolescent Idiopathic Scoliosis (AIS) is performed on standing PA X-ray images, and Cobb angle (CA) is considered the "golden" standard for 2D diagnosis. This study aims to examine optically-assessed spatial angles of AIS as CA inadequately capture the spatial aspects of the deformity. Most relevant angles to capture the complexity of the spinal geometric alignment and facilitates the development of a new method for classifying AIS in 3D are between vertebrae Th1-Th3, Th3-Th12, and Th12-L4 describing proximal thoracic (PT), main thoracic (MT) and lumbar (L) regions.

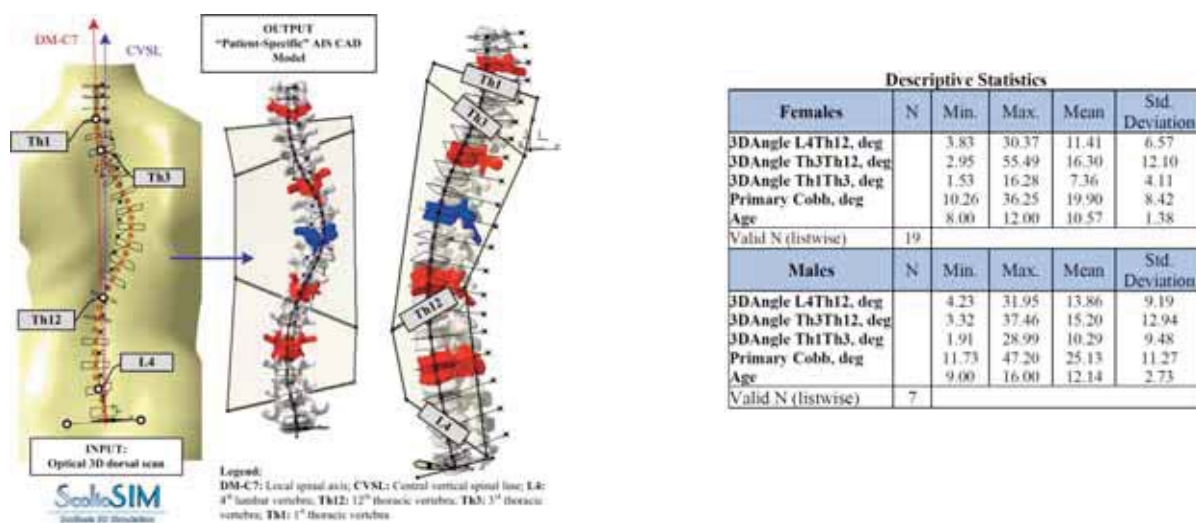


Fig. 1: Spatial angles defined through Th1, Th3, Th12, and L4 vertebrae in a subject-specific model of AIS generated by ScolioSIM tool – Back and 3D view of AIS and descriptive statistics of the measurements

Introduction: AIS is the most common type of spinal deformity in adolescents [1]. Current diagnostic and monitoring methods are based on harmful ionizing radiation. To overcome this potential threat, non-invasive 3D optical measurements offer a powerful solution. One of the latest diagnostic solution that automatically generates deformity parameters is ScolioSIM1.0 [2]. It relies on a multiscale and registerable 3D generic spinal model that auto-adapts to various shapes and sizes of the subject's back (Figure 1).

Methods: Retrospective analysis of 3D optical datasets of 26 AIS patients' back surfaces (19 females and 7 males; 10.5 ± 1.3 and 12.1 ± 2.7 years old, $CA > 10$ deg, 19.9 ± 8.4 deg and 25.1 ± 11.2 deg) was performed using ScolioSIM1.0 tool. Diagnostic indicators were processed using SPSS with a primary focus on three critical spatial angles that describe the three most important segments of the deformed curve (3D Angle L4Th12, 3D Angle Th3Th12, and 3D Angle Th1Th3).

Results and discussion: By measuring spatial angles of the deformity it is possible to evaluate a level of helicoidal torsion of the 3D spinal alignment in certain regions: PT and MT as well as L segments. This analysis showed that the MT region had the highest angular values in females and males (16.3 ± 12.1 and 15.2 ± 12.9). These angles also divide 3D spinal alignment in 3 most significant curvature segments through exact vertebrae centroids suitable for AIS 3D classification.

Conclusions: The clinical relevance of this surface-based approach is high considering the generated deformity angles are suitable for characterizing the most relevant segments of the 3D spinal alignment compared to 2D CA. These findings also reinforce the need to investigate other measurements, especially spatial inflection points and angles in mid-thoracic and thoracolumbar regions and their correlation with axial vertebral rotations.

Acknowledgments: This project was partially funded by the EU H2020 research and innovation programme under the Marie Skłodowska-Curie grant agreement No.892729 and Serbian Ministry of Science under the project III-41007 (2012-2019).

References:

- [1] Luković et al. (2019). *Comput Meth P Bio*, 178: 247-263.
 [2] Cuković S. (2015) PhD Thesis; University of Kragujevac.